



Daniel Edelhoff

## Anterior restorations: The performance of ceramic veneers

Daniel Edelhoff, Prof Dr med dent<sup>1</sup>/Otto Prandtner, MDT<sup>2</sup>/Reza Saeidi Pour, Dr med dent<sup>3</sup>/Anja Liebermann, Dr med dent<sup>4</sup>/Michael Stimmelmayer, Prof, Dr med dent<sup>5</sup>/Jan-Frederik Güth, Priv-Doz, Dr med dent<sup>6</sup>

Adhesive bonding techniques in combination with tooth-colored restorative materials are one of the greatest achievements of restorative dentistry. Adhesively bonded veneers made from various silicate ceramic materials have contributed significantly to this. Ceramic veneers had long been considered to be only esthetic implements. However, their range of indications has been steadily increasing, making ceramic veneers a highly viable alternative to classic, far more invasive forms of restorative treatment. Today these veneers are used to restore the biomechanics of the dentition, to establish adequate function, to mask highly discolored endodontically treated teeth, and for many other

purposes. The present article explains the principles of modern veneer technology based on clinical examples, with special emphasis on collaboration with the dental laboratory and communication within the dental team. This includes analyzing the case, defining the treatment goal, determining the right shade, selecting the most suitable ceramic material, finding the best preparation design, and choosing the most appropriate adhesive concept. The article will also explore the long-term prognosis of ceramic veneers as reported by a number of scientific studies. (Originally published, in German, in *Quintessenz* 2017;68:1–6; *Quintessence Int* 2018;49:89–101; doi: 10.3290/j.qi.a39509)

**Key words:** adhesive bonding, all-ceramics, analysis, material selection, preparation technique, preparation template, shade taking, try-in, veneer, wax-up

The initial concepts for using tooth-colored shells on anterior teeth can be traced back to Charles L. Pincus, who described this technique for the first time in the 1930s.<sup>1</sup> Pincus used this method for changing the appearance of the anterior dentition to support the individual expres-

sions of personality and character – especially targeting actors during film shootings. The durability of these first veneers, however, was limited to a few hours, since at that time neither reliable, well-fitting ceramic systems nor reliable adhesive bonding technologies were available.

<sup>1</sup> Director and Chair, Department of Prosthetic Dentistry, University Hospital, LMU Munich, Munich, Germany.

<sup>2</sup> Master Dental Technician, Platform Dental Laboratory, Munich, Germany.


<sup>3</sup> Assistant Professor, Department of Prosthetic Dentistry, University Hospital, LMU Munich, Munich, Germany.

<sup>4</sup> Assistant Professor, Department of Prosthetic Dentistry, University Hospital, LMU Munich, Munich, Germany.

<sup>5</sup> Specialist in Oral Surgery, Department of Prosthetic Dentistry, University Hospital, LMU Munich, Munich, Germany.

<sup>6</sup> Associate Professor, Department of Prosthetic Dentistry, University Hospital, LMU Munich, Munich, Germany.

**Correspondence:** Prof Dr med dent Daniel Edelhoff, Department of Prosthetic Dentistry, University Hospital, LMU Munich, Goethestraße 70, D-80336 Munich, Germany. Email: daniel.edelhoff@med.uni-muenchen.de



Ceramic veneers became a prominent feature within restorative dentistry, a position they enjoy to this day, only after several important preconditions were fulfilled: the introduction of the acid-etching technique by M.G. Buonocore<sup>2</sup> in the mid-1950s, the development of bonding materials based on bisphenol glycidyl methacrylate (bis-GMA) by R.L. Bowen<sup>3</sup> at about the same time, the establishment of suitable etching processes for silicate-based dental ceramics, and the use of bonding agents such as silane coupling agent.<sup>4-6</sup>

In the initial phases, the veneers were mainly produced using sintering technology on a platinum foil or a refractory die,<sup>7,8</sup> but pressing techniques<sup>9,10</sup> and computer-aided design/computer-assisted manufacture (CAD/CAM) methods<sup>11</sup> soon became available, and demand for them continues to grow. The strength of the materials used has been significantly improved in recent years by the introduction of new types of ceramics.<sup>12</sup>

Encouraged by positive long-term clinical results, there has been a steady expansion of the range of indications, even going so far as to reevaluate previous contraindications and consider them as possible new fields of application.<sup>13-16</sup> Against this backdrop, ceramic veneers have been able to shed their reputation of purely esthetic adjuncts over the decades, becoming a serious treatment alternative in addition to classic and far more invasive types of restorations. Today veneers are also used to restore the biomechanics of the dentition, to establish adequate function, to mask highly discolored endodontically treated teeth, and for many other purposes.

Veneers have much thinner walls than classic crown restorations, with some of them merely requiring additive procedures. Communication within the dental team is therefore essential, whether regarding shades or regarding the selection of the most suitable ceramic material with the appropriate preparation, production, and adhesive techniques.

However, the survival rate of ceramic veneers is influenced by numerous parameters, including the thickness of the available enamel, the material used, the design of the preparation, tooth function and occlusion, the degree of destruction present, and the vitality of the tooth to be treated (vital or endodonti-

cally treated), as well as the level of experience of the restorative team.

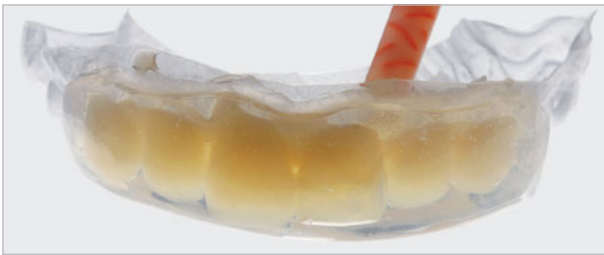This article is intended to offer guidelines for a team approach, allowing the dentist and the dental technician to implement long-lasting and esthetically and functionally successful ceramic veneers.

## IDENTIFICATION AND DEFINITION OF THE RESTORATIVE GOAL

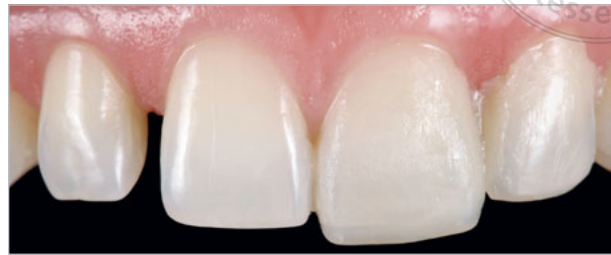The analysis of functional, esthetic, biomechanical, and restorative goals requires the dentist to communicate closely with the dental technician. The following documentation should be available for a laboratory analysis prior to production of the diagnostic wax-up: frontal and lateral portrait photographs with and without face-bow, photographs with the mouth slightly opened and the upper lip relaxed, as well as video recordings, in which the patient freely associates and, for example, counts from 50 to 55. These images facilitate determining the lengths and inclinations of the incisal edges of the maxillary central incisors, which are the central starting point for any anterior or more complex rehabilitation. Further required documentation includes intraoral photographs of both arches, impressions (preferably with a precision impression material) of both arches that reproduce the vestibular area including the alveolar jugae, plus a jaw relation record (in maximum intercuspation and in centric relation if available).

The following points form the basis for the analysis by the dentist/dental technician team:

- Functional analysis in the articulator and on the patient (canine guidance, articulator, patient)
- Occlusal contacts in static and dynamic occlusion (patient, canine guidance, articulator)
- Tooth wear, differentiated by mechanical or biocorrosive origin (patient history, radiographs, intraoral examination, photographs, casts)
- Extent of existing fillings (radiographs, intraoral examination, photographs, casts)
- Tooth proportions, in particular the length of the maxillary central incisors (photographs, video recordings, casts)



**Fig 1** The wax-up was transferred into the patient's mouth with a thermoplastic template/foil (Duran transparent 0.5 mm, Scheu-Dental) that can be combined with a transparent silicone (Matrix Flow 70 clear, Anaxdent).



**Fig 2** For the esthetic evaluation, the anterior teeth were isolated with low-viscosity Vaseline oil, and a mock-up derived from the wax-up was reversibly applied.

- Determination of the number of teeth to be restored (radiographs, intraoral photographs, video recordings, casts)
- Degree of tooth destruction (clinical findings, radiographs, intraoral photographs, casts)
- Position of the midline (portrait photographs, video recordings, casts)
- Angle class (reference: molar relations on the cast and on the patient)
- Axial tooth inclination (lateral/frontal photographs, casts)
- Lip profile (clinical findings, lateral photographs, casts)
- Extent and relationship of overjet and overbite (clinical findings, lateral photographs, casts).

The subsequent wax-up should be carried out with a wax of a color that offers a good contrast with the master cast (eg, light master cast, dark gray wax) to make the borders of the waxed-up parts clearly recognizable. This is important for the subsequent definition and compliance with the preparation margins during the preparation session.

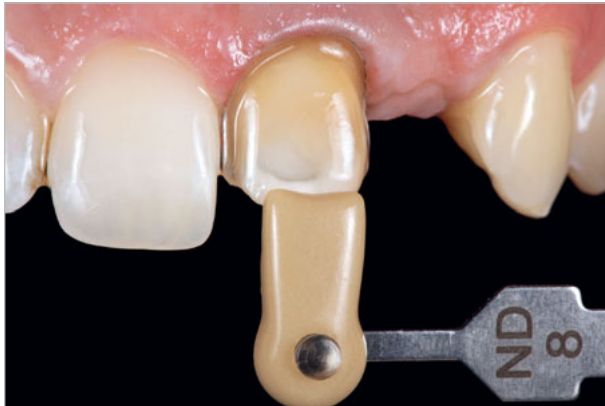The wax-up can be transferred into the patient's mouth either with a thermoforming sheet (such as Duran transparent 0.5 mm; Scheu-Dental) from a duplicated cast (dental stone) or with a transparent silicone (such as Matrix Flow 70 clear; Anaxdent) directly from the cast on which the wax-up was made. A combination of the two (Fig 1) is also possible. For trying in the wax-up in the patient's mouth, materials designed for fabricating chairside provisionals (such as Luxatemp

Automix Solar, DMG) can be used. For this purpose, it is advisable to first isolate the natural teeth with liquid Vaseline oil in order to ensure uncomplicated removal, for example with a scaler (such as a scaler SHG 6/7; Hu-Friedy) (Fig 2).

## SHADE TAKING

The shade should be determined no later than at the beginning of the tooth preparation session. It is important to make a clear decision about the definitive tooth shade together with the patient. Any oral hygiene and bleaching procedures should have been completed at this point.

In general, the tooth's brightness (value) is a far more important factor than the actual tooth shade. In addition, there are considerable differences in brightness between the (lighter) incisors and the (darker) canines in natural teeth.<sup>17</sup> If it is difficult to decide between two brightness levels, it is usually advisable to choose the brighter one. If, for example, Vita Classical A2 is selected in the anterior region, the recommendation for the veneer shade usually inclines towards A1. Due to its enamel-like translucency, an A1 veneer will exhibit a so-called chameleon effect. Due to the visually dominant natural dentin aspect of the prepared tooth, the final shade, once the translucent ceramic veneer has absorbed moisture in the mouth, will develop into an A2, losing some of its brightness. The dental technician can, if needed, render a shade that is too bright



**Fig 3** Determining the die shade of a veneer preparation on a severely discolored, bleaching-resistant central incisor (die shade guide IPS Natural Die Material, Ivoclar Vivadent).

somewhat darker by staining. On the other hand, it is nearly impossible to use staining to brighten a shade that is too dark.

It is essential that the closest shade tabs (reference shades) are photographed together with the residual dentition under identical lighting conditions. In addition, the low layer thickness of veneers mandates, especially in the case of discolored teeth, a second shade determination with a shade guide system for the prepared tooth (eg, IPS Natural Die Material, Ivoclar Vivadent) after completion of the preparation (Fig 3). This information can be used by the dental technician to produce identical-shade laboratory dies in order to optimally adjust the degree of translucency/opacity of the veneer to the substrate: more translucent materials for an intimate interplay with the substrate for a normally colored tooth or opaque layers for masking a severely discolored background.<sup>18</sup>

## MATERIAL SELECTION

The material, too, should be selected ahead of the tooth preparation session if possible. In principle, indirect veneers made of composite materials could also be used.<sup>19</sup> However, in recent decades, veneers based on various silicate ceramic materials have come to predominate because their mechanical and optical prop-

erties resemble those of tooth enamel, and thanks to their excellent adhesive options with hydrofluoric acid etching and the application of silane. Ceramic veneers can be produced by various methods that also influence the choice of material:

- Sintering on platinum foil or refractory dies (superior esthetics, relatively low strength)
- Pressing or CAD/CAM, monolithic, stained (reduced esthetics when using monochromatic materials, highest strength)
- Pressing or CAD/CAM, with a minimal enamel veneer on a framework designed as a dentin core structure, the so-called “cut-back” technique (very good esthetics, high strength)
- Pressing or CAD/CAM, with a more extensive veneer of a framework (very good esthetics, high strength).

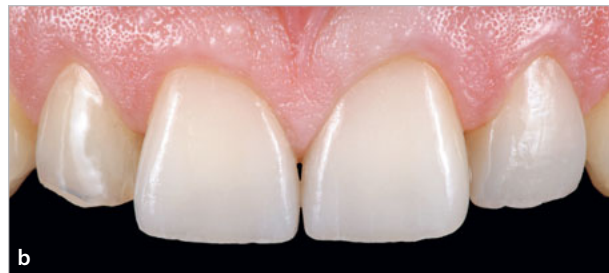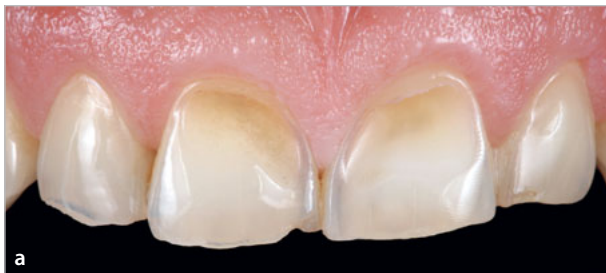For each of these methods, different silicate ceramic materials are available. The entire range of materials available cannot be presented within the limited scope of this article; only a few examples will therefore be listed. Both classic feldspathic ceramics (such as Creation CC, Willi Geller) and modified versions of these like leucite-reinforced fluorapatite ceramics (such as IPS d.SIGN, Ivoclar Vivadent) can be used for the sintering technique. These ceramics fall into the category of veneering ceramics and have relatively low bending strengths of only up to 100 MPa.<sup>20</sup>

Materials offered for pressing or CAD/CAM include feldspathic CAD/CAM ceramics (Vitablocs Mark II, Vita Zahnfabrik), leucite-reinforced glass ceramics (such as IPS Empress and IPS Empress CAD; Ivoclar Vivadent), zirconia-reinforced lithium silicate ceramics (such as Celtra Press or Celtra Duo, Dentsply Sirona Prosthetics; or Vita Suprinity, Vita Zahnfabrik), and lithium disilicate ceramics (such as IPS e.max Press or IPS e.max CAD; Ivoclar Vivadent). Clinical studies have shown that feldspathic ceramics, leucite-reinforced glass ceramics, and lithium disilicate ceramics all achieve highly satisfactory long-term results.<sup>6,10,21,22</sup>

To the best of the authors’ knowledge, no long-term clinical data are currently available for veneers made of zirconia-reinforced lithium silicate ceramics, as these have only been on the market for a few years. A



<b>Table 1 Suggested classification of ceramic veneers according to layer thickness and according to whether esthetic appearance or strength is the primary consideration</b>			
	<b>“Thin” veneers</b>	<b>Classic veneers</b>	<b>“Thick” veneers</b>
Minimal layer thickness	≥ 0.3 mm	≥ 0.5 mm	≥ 0.6 mm
Esthetics	Sintered ceramic, refractory die	Sintered ceramic, refractory die	
Esthetics/function		Cutback, framework made of lithium (di) silicate ceramic with veneering ceramic	Framework made of lithium (di) silicate ceramic with veneering ceramic
Function	Monolithic lithium (di-)silicate ceramic	Monolithic lithium (di-)silicate ceramic	Monolithic lithium (di-)silicate ceramic



**Figs 4a and 4b** Example of a veneer restoration in a male patient with parafunctional habits. Due to the increased fracture risk, the veneers were made of a monolithic high-strength lithium disilicate ceramic (IPS e.max Press HT, Ivoclar Vivadent). The esthetic appearance cannot compete with sintered veneers with a ceramic build-up. However, the latter exhibit far less strength.

possible practical guide for selecting the most suitable production technique as used by the authors is presented in Table 1. It distinguishes between “thin” veneers with a minimum thickness of 0.3 mm, “classic” veneers with a minimum thickness of 0.5 mm, and “thick” veneers with a minimum thickness of 0.6 mm for restoring extensive hard-tissue defects.

If the primary consideration is maximum esthetic requirements and if functional risk can be largely excluded, thin and classic veneers made of sintered ceramics would be the authors’ first choice. If residual functional risks such as unfavorable occlusal conditions (deep overbite, steep guide inclines), possible parafunction, and high chewing forces are expected, monolithic veneers based on lithium (di-)silicate ceramics should be preferred, appropriately stained, or with chromatically differentiated dentin and enamel aspects (Fig 4) using multichromatic CAD/CAM blocks (such as

IPS Empress CAD Multi, Ivoclar Vivadent) or pressable blanks (IPS e.max Press Multi, Ivoclar Vivadent). The advantage of extremely high strength is to some extent counterbalanced by a certain necessary amount of esthetic compromise (Fig 4b).

A framework made of lithium (di-)silicate ceramics with a sintered veneering ceramic combines the advantages of these two approaches. Where only little space is available, this type of restoration can be implemented using strictly enamel sintering ceramics on a dentinal core-type framework (cut-back technique); in more voluminous restorations, multiple layers can be applied. In the case of layers of several millimetres to restore even greater volumes or tooth parts, a framework structure should be preferred to improve strength.



## PREPARATION

Minimally invasive preparations, such as those for veneers, place higher demands on practitioners' skills than far more invasive full-crown preparations. On one hand, the preservation of tooth enamel under the veneer is an essential factor that determines the success of the treatment.<sup>22,23</sup> On the other hand, a more invasive preparation for the veneer offers the dental technician greater freedom of design and provides the dentist with both simpler options for provisionalization and a more clearly defined position for definitive adhesive bonding. While the design of veneer preparations is governed by strict design principles, these preparations can still be extremely flexible in shape, depending on the individual clinical situation (extent of functional and esthetic corrections required, degree of tooth destruction, existing fillings, occlusal conditions, etc). This applies to the position of the cervical preparation margin and to the incisal design as well as to the interproximal extension.

The cervical preparation margin can be placed supragingivally, equigingivally, or intrasulcularly. A supragingival preparation margin offers numerous advantages such as the presence of enamel, simpler preparation and impression, good control of the adhesive cementing process (excess removal), and no traumatic interference with the marginal gingiva. An intrasulcular preparation is suitable for more extensive morphologic changes, for closing interdental spaces such as "black triangles," or for covering exposed dentin/root cement or existing composite fillings.

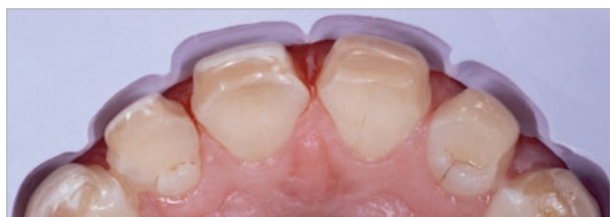In terms of the incisal design, the preparation of a palatal chamfer provides the highest degrees of freedom for defining the positions of the incisal edge – for instance, further vestibularly for added lip support – without resulting in an excessively "thick" incisal-edge design. No differences in strength were detected between different incisal preparation options with and without incisal coverage.<sup>24</sup>

Using the wax-up to define the external contours of the future veneer has two advantages. On one hand, the positions of the preparation margins as requested

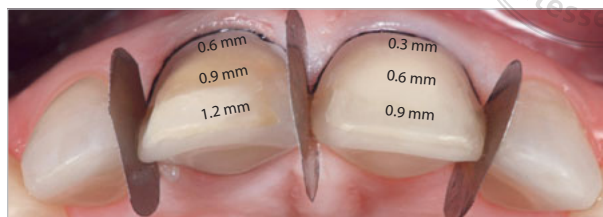
by the dental technician can be checked on the wax-up itself; on the other hand, a diagnostic template or silicone key derived from the wax-up can be used to carry out a guided preparation that can be verified at any time (Fig 5).

In the present of severe discoloration, the preparation depth should be increased to provide the dental technician with enough space to mask the discoloration (Fig 6). The cut-back depth can be easily checked by means of a periodontal probe with millimeter graduation (eg, CP-15 UNC, Hu-Friedy), which measures the distance between the prepared tooth surface and the interior surface of the prep-guide. Alternatively, the preparation depth can be controlled by using depth-marking diamonds on the mock-up. These will make the non-diamond shank of the depth marker stop at the predefined contact surface of the future veneer. Thanks to the predominantly additive veneering concept, hard tissue will be removed only where minimum wall thickness requirements would not be met (Fig 7).

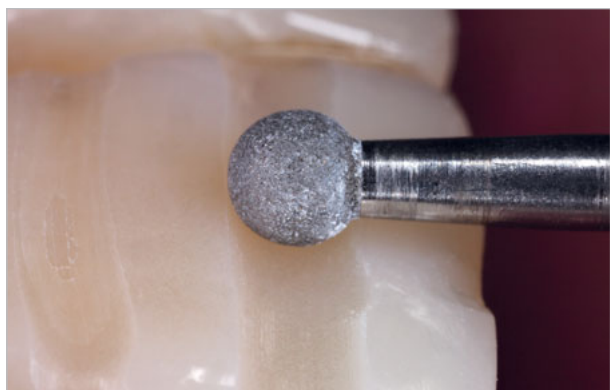
An interproximal extension of the preparation can also be performed to varying degrees, depending on the initial situation and on the restorative objective (Fig 8). While the less invasive, simple, and quick-to-implement short-wrap design leaves the preparation margins in the visible area, the more frequently employed medium-wrap design hides the preparation margins in the interproximal niches, but stays clear of the points (Fig 9). Retaining the contact points results in the width of the existing tooth being preserved, limiting the possibility of altering the tooth length to match the desired predefined width-to-length ratio.<sup>25</sup> The long-wrap design is significantly more invasive because it opens the contact points. On the other hand, it offers the restorative team considerably more options when it comes to veneer shapes and positions. This preparation design is particularly suitable for severely discolored teeth, for closing diastemas and so-called "black triangles," for adjustments midline, for extensive changes in tooth shapes, and for covering more extensive proximal fillings. In the case of veneers in the immediate neighborhood of crowns, the long-wrap variant is advantageous because it



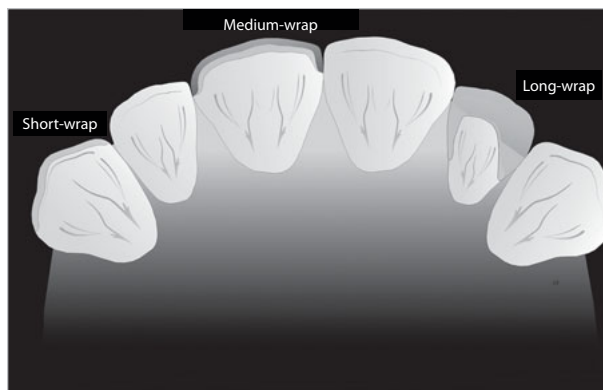
**Fig 5** Preparation. The outer contour, which had been planned by means of a wax-up, was transferred to a diagnostic template made of a silicone material. This template served as a guide during preparation and ensured that only as much hard tissue as strictly necessary was removed.



**Fig 6** Preparation. Veneer preparation of the two maxillary central incisors using a medium-wrap design. Prior to the putty/wash impression, metal matrices were inserted in the regions of the interdental contacts to avoid having to saw-cut the master cast. Due to the pronounced discoloration of the right central incisor, slightly more hard tissue was removed here (for easier masking) than on the nondiscolored contralateral tooth.



**Fig 7** Preparation. Use of a depth marker on the mock-up to define the external surface of the planned veneer. This ensured that hard tissue was removed only where the minimum thickness of the veneer could not otherwise have been achieved.



**Fig 8** Design options for the interproximal extension. From left to right, these have increasing levels of invasiveness. Short-wrap design: easy to implement, but with a visible adhesive joint. Medium-wrap design: retaining the contact point and with the adhesive joint not visible. Long-wrap design: with removal of the contact point and a deeper (approximately two-thirds) interproximal preparation.

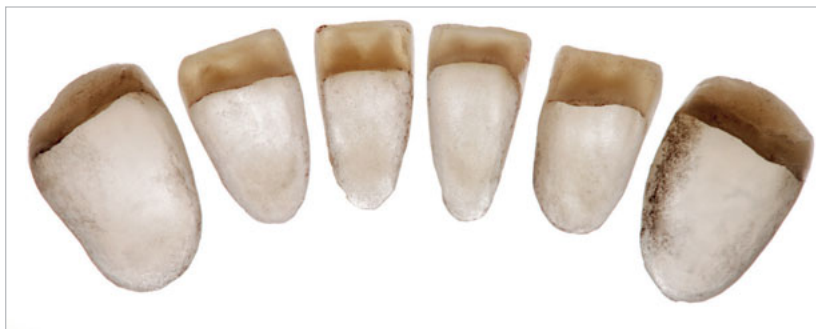allows the contact point between the two restorations to be realized in ceramics.

Oscillating instruments (such as SF8878KM “half-torpedo” SonicLine tips, Komet Dental) are available for interproximal chamfer preparations; for edge breaking, rounding, and smoothing, polishing disks (SofLex XT pop-on disks, medium grain, 2382 M; 3MEspe) can be used (Figs 10 and 11).<sup>26</sup>

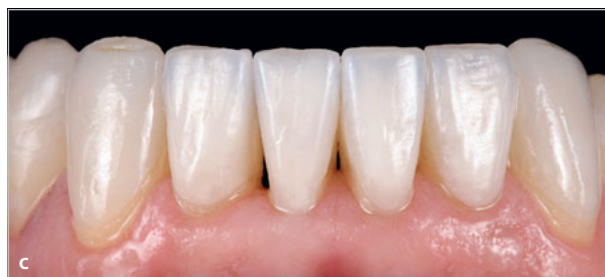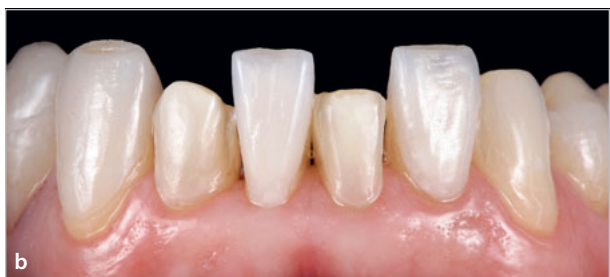For periodontally compromised situations, the long-wrap design can be combined with a horizontal axis of insertion. This can help to avoid a large amount of hard tissue removal in the coronal area of the tooth, and the

cervical distance (C) can be kept smaller than the incisal distance (D) (Fig 12).<sup>27</sup> However, this method must be classified as very difficult in terms of its clinical and technical implementation.

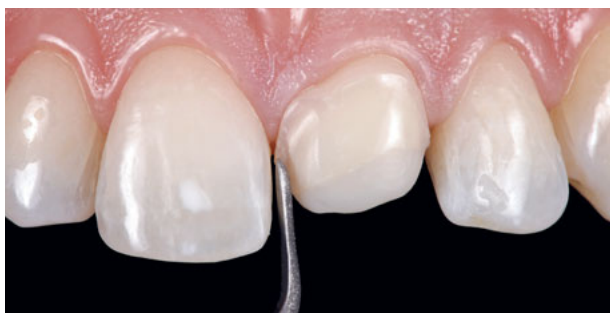In certain indications, it may be difficult to tell the difference between this solution and a full crown (Fig 13). This circular (360°) form of preparation is also referred to as a full-wrap design. It is particularly suitable for complex cases that require an increase in the vertical dimension of occlusion, where it can be used to help to close, at least partially, the resulting gap between maxillary and mandibular anteriors (Fig 13).<sup>28</sup>



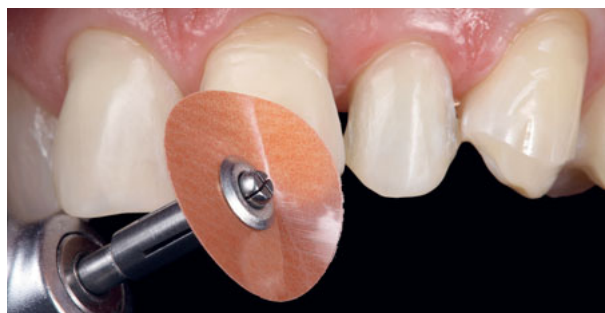**Fig 9a** Example of a veneer preparation of the mandibular anterior teeth using a medium-wrap design (“thin” veneers). In this case, the veneers for the four incisors were made of feldspathic ceramics sintered on refractory dies, while the monolithic veneers for the two canines were made of pressable lithium disilicate ceramics to achieve greater strength.



**Figs 9b and 9c** Try-in of the veneers in Fig 9a with stained glycerin-based try-in pastes (shade “warm”).



**Fig 10** Using an oscillating “half torpedo” to create a proximal chamfer for a veneer preparation in full-wrap design. A diamond coating was present only on one side of the instrument, which prevented trauma to the adjacent tooth during preparation.



**Fig 11** Use of a one-side coated Sof-Lex disk (2382 M, 3MEspe) for edge breaking, rounding, and smoothing of the veneer preparation previously produced with diamonds.

## PROVISIONALIZATION

Provisional restorations can be created chairside using the multiple-use diagnostic preparation template and a bis-GMA-based provisional restoration material (such as Lux-atemp Automix Solar, DMG). The surrounding hard and soft tissues can be isolated with liquid Vaseline oil.

To improve the esthetics of the provisional maxillary veneers, a light-curing translucent composite resin (such as Tetric Evoflow in shade T, Ivoclar Vivadent) can

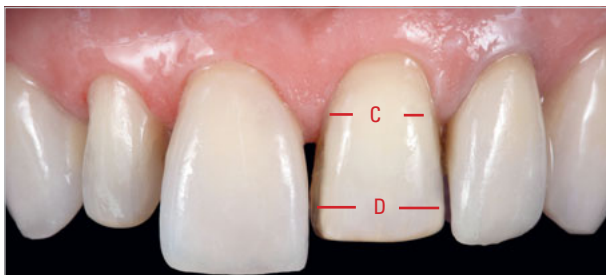
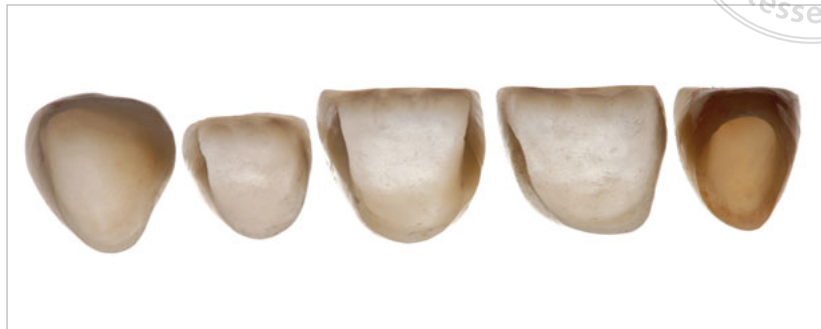be added to the incisal edge area of the template in the fabrication phase, which is given a tapered edge and then briefly photopolymerized and lined with a bis-GMA-based temporary restoration material. Both materials can be easily retrieved from the template.

Low-retention provisional veneers are best left splinted if possible and inserted using an adhesive (such as Heliobond, Ivoclar Vivadent) previously applied with a brush to the finely unetched preparation surfaces and to the internal surfaces of the provisionals.

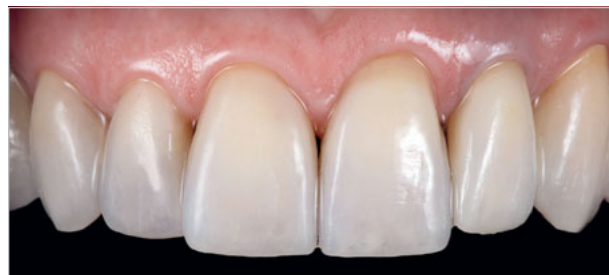



**Fig 12a** Long-wrap ceramic veneers from maxillary right canine to left central incisor, and all-ceramic crown for the maxillary left lateral incisor.



**Fig 12b** The veneer preparation on the left central incisor was designed for a horizontal insertion axis. As a result, the cervical distance (C) could be kept smaller than the incisal distance (D) (which would lead to an undercut seen from the vertical perspective). Compared with a traditional full-crown preparation, about 40% of the hard tissue of the tooth could be preserved.



**Fig 12c** Situation after adhesive bonding of the long-wrap veneers with light-curing low-viscosity adhesive resin (Variolink Esthetic LC, shade “warm”; Ivoclar Vivadent) and the crown on the left lateral incisor with a dual-curing adhesive resin (Variolink Esthetic DC, shade “warm”; Ivoclar Vivadent).

After removing the excess with foamed plastic pellets (Pele Tim, Voco) and Superfloss (Oral B), the adhesive layer is cured through the provisional restoration by a polymerization lamp for 30 seconds. In cases with extremely low retention, so-called “spot etching” (phosphoric acid etching of a small circular enamel area within the preparation surface, about 2 mm in diameter, for only 10 seconds) is recommended before delivery of the provisional. The partial microstructure relatively reliably prevents the loss of retention after the adhesive has been cured.

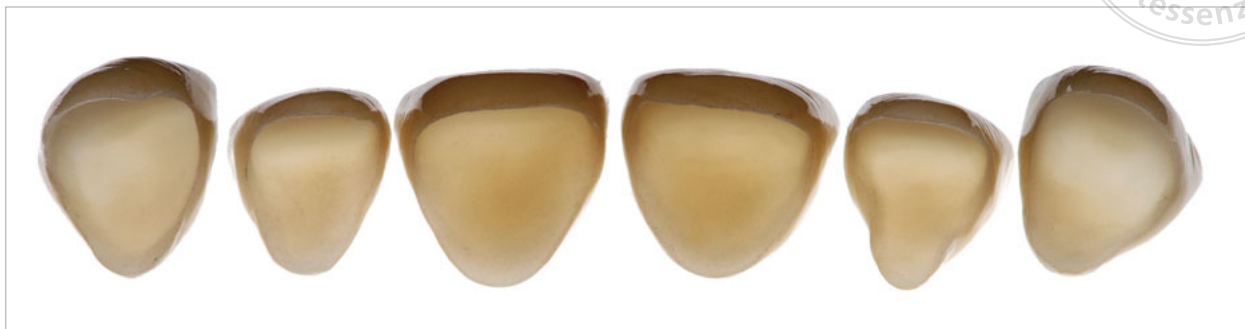
Temporaries are also helpful in checking whether enough hard tissue has been removed, as they precisely represent the thickness of the future ceramic veneer. Therefore, it makes sense to fabricate them before taking the final impression and to check their thickness with a caliper. In this case, however, the contaminated tooth surfaces should be cleaned, prior to the precision impressions, with rotating nylon cleaning

brushes (such as 9531.204.020, Komet Dental) to avoid any interference between remnants of the temporary and the precision impression material.

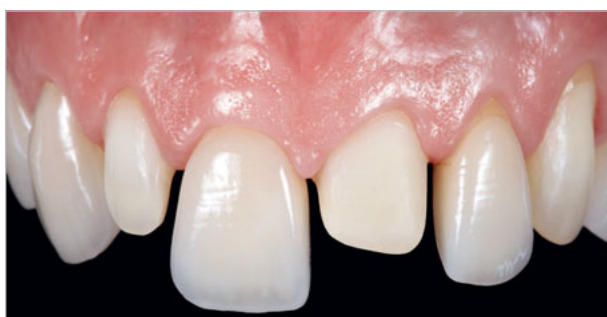Ahead of taking a precision impression of the intra-sulcularly prepared teeth, it is advisable to place two retraction cords into the sulcus positioned on top of each other (Ultrapak, size #000 as first and #0 as second filament; Ultradent). In the case of equi- and supragingival preparations, the single-strand technique using a size #000 is usually sufficient. The impression itself should be a single-stage putty/wash impression (for example using polyether, Impregum/Permadyne, 3MEspe) in a custom tray or individualized Rimlock impression tray previously prepared with polyether adhesive.

## TRY-IN AND ADHESIVE CEMENTING

After removing the provisionals, the sites are cleaned with nylon cleaning brushes and a fluoride-free clean-



**Fig 13a** Ceramic veneers with a framework of lithium disilicate ceramic (IPS e.max Press HT, Ivoclar Vivadent) with manual veneering using a full-wrap design with circular (360°) preparation.



**Fig 13b** Ceramic veneers with a full-wrap design at the try-in with try-in paste. The preparation was located equi- and supragingivally and exhibited a continuous labial enamel zone.

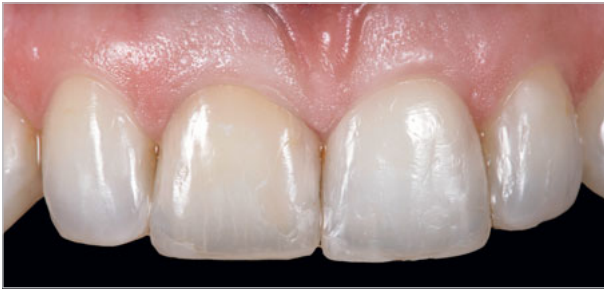ing paste (Zircate Prophy Paste, Dentsply Sirona). In most cases, the adhesive will detach automatically as the provisionals are removed from the finished prepared surfaces. Stubborn adhesive residue can be easily removed with a scaler. On selectively etched enamel surfaces, finishing burs or Sof-Lex disks can be used to remove any adhesive.

To check the shape and shade of the restorations, they are tried in using colored glycerin gel (such as Variolink Esthetic try-in paste, Ivoclar Vivadent), available in colors corresponding to the definitive adhesives (warm+, warm, neutral, light, light+). The try-in pastes can be used to test minimal last-minute shade adjustments to the veneers. Their influence is not very pronounced, but it increases with increasing translucency and with decreasing thickness of the veneer (Fig 14).<sup>29</sup>

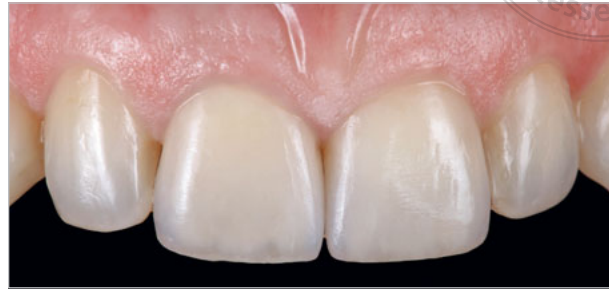The marginal fit can be inspected using a self-mixing A-silicone compound (Fit Test C & B, Voco).

During the try-in, silicate ceramic restorations – and especially veneers – are highly prone to fracture and require a high level of patient compliance. To clean the interior surfaces of the ceramic veneers contaminated by the try-in, nylon brushes should be used and the veneers should be thoroughly rinsed. The internal surfaces of the restorations are then etched with hydrofluoric acid gel (such as IPS Ceramic Etching Gel, Ivoclar Vivadent).

Depending on the type of ceramics used, the etching times can vary considerably, from 20 seconds (lithium disilicate ceramics) to 90 seconds (sintered feldspathic ceramics). Therefore, the dental technician should provide the practitioner with appropriate information on the ceramic material used. To remove residual acid, the etched restorations are sprayed with a water/air mixture for 30 seconds, and the acid is neutralized (IPS Ceramic Neutralizing Powder, Ivoclar



**Fig 14a** Frontal view of the baseline situation from Fig 6. The maxillary right central incisor had been endodontically treated following trauma; it was discolored and resistant to bleaching.



**Fig 14b** Frontal view 48 months after adhesive bonding of two veneers made of sintered feldspathic ceramic on refractory dies (Creation CC, Willi Geller). For an additional esthetic touch, the veneer on the severely discolored right central incisor was bonded with Variolink Esthetic LC in "light+," while the veneer on the nondiscolored left central incisor was bonded with the same adhesive in the color "warm."

Vivadent). Submersion in an ultrasonic bath or careful steam-cleaning evaporation can additionally be helpful in removing persistent excess material.

Following visual inspection of the etching pattern, a primer (such as the effective silane component of Monobond Plus, exposure time 60 seconds) is applied, which establishes a chemical bond between the adhesive and the silicate ceramic. Applying heat significantly increases the priming effect, as this allows the adhesive molecules to condense on the ceramic surface. This can be achieved with a common hairdryer.<sup>30</sup> When using a low-viscosity adhesive such as Variolink Esthetic, no bonding layer needs to be applied to the restoration. This also eliminates the need to protect the preconditioned veneers from light.

The next step should be additional mechanical cleaning of the preparation surfaces with brushes and fluoride-free pumice paste. If placing rubber dam is difficult, for example in the case of an intrasulcular preparation, the use of non-impregnated gingival retraction cords (such as UltraPak size #000, Ultradent) is recommended; these are placed into the sulcus below the preparation margin.

For more extensive core buildups, additional roughening with a coarse-grained diamond grinding wheel at low speed (2,000 rpm, red angled handpiece) without irrigation is recommended. An alternative to roughening the core with diamond cutters is the use of an

intraoral airborne particle-abrasion instrument, which can also be used for the silica-coating of surfaces.<sup>31</sup>

In addition to Total Etch & Rinse systems, universal adhesive systems with selective etching are also suitable for conditioning the prepared tooth surfaces. In the case of thin and classic veneers with high translucency, strictly light-curing, low-viscosity adhesive resins (such as Variolink Esthetic LC, Ivoclar Vivadent) can be used. These are applied to the prepared surfaces as well as to the internal surfaces of the restoration.<sup>32</sup>

In order to keep the veneers from "floating" on the tooth surface ("contact lens effect"), a first spot exposure (for example with Light Probe Pin Point 6 > 2 mm, Bluephase Style 20i; Ivoclar Vivadent) is recommended for topical polymerization after placement and position checking and an initial excess removal. This keeps the restoration from changing its position without fully polymerizing the excess, which would make it difficult to remove. Initial light-curing for only a few seconds transforms the adhesive resin excess into a gel-like state so that it can be removed with a scaler (for example SH 6/7; Hu-Friedy) and Super Floss, keeping the positions of the restorations stable.

After removing the excess, but before the final curing step, a glycerin gel (such as Liquid Strip, Ivoclar Vivadent) should be applied to the margins to prevent the formation of an oxygen inhibition layer. For complete polymerization, it is recommended to expose each



occlusal, oral, and vestibular surface (if necessary accompanied by mild air cooling) for 40 seconds. A powerful polymerization lamp ( $> 1,000 \text{ mW/cm}^2$ ) should be used for the definitive curing. After curing, the retraction cords should be removed and the sulcus carefully cleaned of excess resin with the aid of a scaler or scalpel.

Following adhesive cementing and excess removal, the static and dynamic occlusion should be checked for the presence of interferences and premature contacts. Fine-grained diamond grinding wheels (red ring) with irrigation are used for final adjustments of the static and dynamic occlusion. The adjusted surfaces should then be smoothed with a ceramic polisher (for example 9545F 204 110, Komet Dental).

## DISCUSSION

In theory, composite resin should also be suitable for use as a restorative material for veneers. However, in a clinical study, composite-based veneers showed a lower survival rate after 3 years than those made from leucite-reinforced glass ceramics.<sup>19</sup>

As for silicate ceramic veneers, there had already been numerous clinical studies as early as 15 years ago with sometimes extensive observation periods and covering a high number of restorations.<sup>23,33</sup> Fractures of all-ceramic veneers or of veneering ceramics on a framework are still among the most frequent causes of failure.<sup>21</sup>

In a retrospective clinical study of feldspathic ceramic veneers made on refractory dies, 155 restorations were randomly selected from a pool of 499 veneers evaluated after 20 years, yielding a cumulative survival rate of 91%. The authors pointed out that the cases evaluated featured sufficient enamel coverage of at least 80% of the preparation area and preparations with marginal chamfers, as well as an incisal reduction with a palatal overlap.<sup>22</sup>

In another retrospective study of 318 veneers made of feldspathic ceramics, leucite-reinforced glass ceramics and lithium disilicate ceramics yielded calculated clinical survival rates of 93.5% after 10 years and 82.76% after 20 years.<sup>21</sup> Margin discoloration was

counted as a relative failure; it occurred in 21.9% of cases, predominantly in smokers. A dynamic occlusion concept that protected the canines was identified as one of the factors for success.

The adhesive technique, which used light-curing composites exclusively, was rated positive in a clinical study of 119 ceramic veneers and an observation period of up to 7 years, with a survival rate of 97.5% and a margin discoloration rate of only 2.5%.<sup>34</sup> In a clinical trial, the practitioner's experience in the field of adhesive cementing technology has had significant impact on the survival rate of all-ceramic restorations.<sup>35</sup>

Preliminary clinical results of a prospective clinical study of long-wrap veneers are promising, but the data – like those for full-wrap veneers – are still insufficient.<sup>36</sup>

In the case of extensive restorations, the three-step technique described by Vailati and Belser<sup>16</sup> can also be an alternative to the full-wrap design. This technique first calls for closing the palatal space behind the maxillary anterior teeth that results from increasing the vertical dimension of occlusion using composite resin. In a second step, the labial surfaces receive adhesively bonded ceramic veneer (the so-called sandwich technique).<sup>16</sup> Even though no major failures have occurred after an observation period of up to 6 years, clinical long-term results of multicenter studies must be awaited in order to make a final assessment of this technique.<sup>37</sup>

Major risk factors for ceramic veneers are bruxism, insufficient enamel support, and endodontically treated teeth.<sup>21,23,38,39</sup>

## CONCLUSIONS

Ceramic veneers have developed into a serious treatment alternative in addition to classic, far more invasive restorative approaches. A team approach to proper treatment planning, analysis, and the material selection together with the dental technician, an appropriate preparation design, carefully performed adhesive bonding, and reciprocal occlusal contacts are the foundation for clinically reliable silicate ceramic veneer restorations.



## REFERENCES

- Pincus CR. Building mouth personality. *J Calif Dent Assoc* 1938;14:125–129.
- Buonocore MG. A simple method for increasing the adhesion of acrylic filling materials to enamel surfaces. *J Dent Res* 1955;34:849–853.
- Bowen RL. Use of epoxy resins in restorative materials. *J Dent Res* 1956;35:360–369.
- Bailey LF, Bennett RJ. DICOR surface treatments for enhanced bonding. *J Dent Res* 1988;67:925–931.
- Calamia JR. Etched porcelain facial veneers: a new treatment modality based on scientific and clinical evidence. *NY J Dent* 1983;53:225–229.
- Layton DM, Clarke MA. Systematic review and meta-analysis of the survival of non-feldspathic porcelain veneers over 5 and 10 years. *Int J Prosthodont* 2013;26:111–124.
- Friedman MJ. A 15-year review of porcelain veneer failure: a clinician's observations. *Compend Contin Educ Dent* 1998;19:625–628.
- Sorensen JA, Strutz JM, Avera SP, Materdomini D. Marginal fidelity and microleakage of porcelain veneers made by two techniques. *J Prosthet Dent* 1992;67:16–22.
- Fradeani M, Barducci G. Versatility of IPS Empress restorations. Part II: Veneers, inlays, and onlays. *J Esthet Dent* 1996;8:170–176.
- Fradeani M, Redemagni M, Corrado M. Porcelain laminate veneers: 6- to 12-year clinical evaluation: a retrospective study. *Int J Periodontics Restorative Dent* 2005;25:9–17.
- Wiedhahn K, Kerschbaum T, Fasbinder DF. Clinical long-term results with 617 Cerec veneers: a nine-year report. *Int J Comput Dent* 2005;8:233–246.
- Lawson NC, Bansal R, Burgess JO. Wear, strength, modulus and hardness of CAD/CAM restorative materials. *Dent Mater* 2016;32:e275–e283.
- Rouse JS. Full veneer versus traditional veneer preparation: a discussion of interproximal extension. *J Prosthet Dent* 1997;78:545–549.
- Simonsen RJ. From prevention to therapy: minimal intervention with sealants and resin restorative materials. *J Dent* 2011;39(Suppl 2):S27–S33.
- Stappert CF, Stathopoulou N, Gerds T, Strub JR. Survival rate and fracture strength of maxillary incisors, restored with different kinds of full veneers. *J Oral Rehabil* 2005;32:266–272.
- Vailati F, Belsler UC. Full-mouth adhesive rehabilitation of a severely eroded dentition: the three-step technique. Parts 1–3. *Eur J Esthet Dent* 2008;3:30–44;128–146;236–257.
- Goodkind RJ, Schwabacher WB. Use of a fiber-optic colorimeter for in vivo color measurements of 2830 anterior teeth. *J Prosthet Dent* 1987;58:535–542.
- Chu SJ, Mielelesko AJ. Color-matching strategies for non-vital discolored teeth: part 1. Laboratory ceramic veneer fabrication solutions. *J Esthet Restor Dent* 2014;26:240–246.
- Gresnigt MM, Kalk W, Ozcan M. Randomized clinical trial of indirect resin composite and ceramic veneers: up to 3-year follow-up. *J Adhes Dent* 2013;15:181–190.
- Kappert HF, Krah M. Keramik – eine Übersicht. *Quintessenz Zahntechnik* 2001;27:668–704.
- Beier US, Kapferer I, Burtscher D, Dumfahrt H. Clinical performance of porcelain laminate veneers for up to 20 years. *Int J Prosthodont* 2012;25:79–85.
- Layton DM, Walton TR. The up to 21-year clinical outcome and survival of feldspathic porcelain veneers: accounting for clustering. *Int J Prosthodont* 2012;25:604–612.
- Peumans M, van Meerbeek B, Lambrechts P, Vanherle G. Porcelain veneers: a review of the literature. *J Dent* 2000;28:163–177.
- Albanesi RB, Pigozzo MN, Sesma N, Laganá DC, Morimoto S. Incisal coverage or not in ceramic laminate veneers: a systematic review and meta-analysis. *J Dent* 2016;52:1–7.
- Magne P, Gallucci GO, Belsler UC. Anatomic crown width/length ratios of unworn and worn maxillary teeth in white subjects. *J Prosthet Dent* 2003;89:453–461.
- Faus-Matoses I, Solá-Ruiz F. Dental preparation with sonic vs high-speed finishing: analysis of microleakage in bonded veneer restorations. *J Adhes Dent* 2014;16:29–34.
- Magne P, Belsler U. Chapter 4: Evolution of indications for anterior bonded porcelain restorations. Major morphologic modifications. In: Magne P, Belsler U. *Bonded porcelain restorations in the anterior dentition*. Chicago: Quintessence, 2002:140–142,266–269.
- Edelhoff D, Brix O, Stimmelmayer M, Beuer F. Ästhetische und funktionelle Gesamtrehabilitation eines Patienten unter Einsatz von Lithiumdisilikatkeramik – Ein Fallbericht. *Quintessenz* 2013;64:623–638.
- Xu B, Chen X, Li R, Wang Y, Li Q. Agreement of try-in pastes and the corresponding luting composites on the final color of ceramic veneers. *J Prosthodont* 2014;23:308–312.
- Barghi N, Berry T, Chung K. Effects of timing and heat treatment of silanated porcelain on the bond strength. *J Oral Rehabil* 2000;27:407–412.
- Edelhoff D, Marx R, Spiekermann H, Yildirim M. Clinical use of an intraoral sili-coating technique. *J Esthet Restor Dent* 2001;13:350–356.
- Ilie N, Hickel R. Correlation between ceramic translucency and polymerization efficiency through ceramics. *Dent Mater* 2008;24:908–914.
- Friedman MJ. Augmenting restorative dentistry with porcelain veneers. *J Am Dent Assoc* 1991;122:29–34.
- D'Arcangelo C, De Angelis F, Vadini M, D'Amario M. Clinical evaluation on porcelain laminate veneers bonded with light-cured composite: results up to 7 years. *Clin Oral Investig* 2012;16:1071–1079.
- Frankenberger R, Reinelt C, Petschelt A, Krämer N. Operator vs. material influence on clinical outcome of bonded ceramic inlays. *Dent Mater* 2009;25:960–968.
- Guess PC, Selz CF, Steinhart YN, Stampf S, Strub JR. Prospective clinical split-mouth study of pressed and CAD/CAM all-ceramic partial-coverage restorations: 7-year results. *Int J Prosthodont* 2013;26:21–25.
- Vailati F, Gruetter L, Belsler UC. Adhesively restored anterior maxillary dentitions affected by severe erosion: up to 6-year results of a prospective clinical study. *Eur J Esthet Dent* 2013;8:506–530.
- Burke FJ. Survival rates for porcelain laminate veneers with special reference to the effect of preparation in dentin: a literature review. *J Esthet Restorative Dent* 2012;24:257–265.
- Gurel G, Sesma N, Calamita MA, Coachman C, Morimoto S. Influence of enamel preservation on failure rates of porcelain laminate veneers. *Int J Periodontics Restorative Dent* 2013;33:31–39.