

Innovative Single-Tooth Replacement with an Individual Root-Analog Hybrid Implant in the Esthetic Zone: Case Report



Reza Saeidi Pour, Dr Med Dent¹/Peter Randelzhofer, Dr Med Dent²/Daniel Edelhoff, Prof Dr Med Dent³/Otto Prandtner, MDT⁴/Caroline Freitas Rafael, PhD⁵/Anja Liebermann, Dr Med Dent⁶

The goal of this study was to explore an innovative approach to single-tooth replacement using an individually custom-fabricated, root-analog, hybrid dental implant, in the esthetic zone, to avoid the microgap and micromovements between the implant and abutment. Moreover, the use of burs to prepare the implant recipient site is not necessary in this technique, reducing the bone removal, heating, and trauma. The process requires capturing accurate root geometry through combined computer-aided design/computer-assisted manufacturing (CAD/CAM) and a three-dimensional (3D) visualization (digital volume tomography [DVT]) of the tooth in situ, which might result in reduced remodeling after insertion. A good esthetic and functional outcome was obtained. The use of a root-shaped tooth analog implant might be in selected cases a viable alternative to current threaded cylindrical and cone-shaped implants. The new concept avoids the microgap between the implant and the abutment and reduces the trauma to the tissue and bone. INT J ORAL MAXILLOFAC IMPLANTS 2017;32:e153–e160. doi:10.11607/jomi.5562

Keywords: immediate implant insertion, microgap, patient-individual implant design, root-analog hybrid implant, single-tooth replacement

After a tooth is extracted, the socket and surrounding tissues undergo remodeling.^{1–5} This process leads to soft tissue and bone alterations that can compromise the placement of an implant and the final esthetic of the surrounding tissues. To overcome this limitation and reduce the remodeling, immediate implants are commonly indicated⁵; they additionally minimize treatment time, the number of surgical

interventions, and the overall costs.⁶ However, traditional immediate implant techniques require preparation of the alveolar socket according to the predefined geometry by special burs that can lead to bone trauma, thought to be one of the causes of implant failure.⁷ This trauma causes necrotic bone areas that can compromise osseointegration.⁷ Moreover, the commonly used implants for delayed or immediate placement procedures are prefabricated, presenting mostly threaded cylindrical designs and circular platforms.⁸

Looking for alternatives to improve the results of conventional techniques, a custom-made root-analog implant was first described in 1969⁹ as a technique to reduce bone and soft tissue resorption. This technique cited the importance of avoiding the use of burs to reduce trauma on hard and soft tissue, and customizing an implant according to the alveolar socket shape.^{8–11} The first root-analog implant designs used auto-polymerized and heat-processed poly-methacrylates and resulted in fibro-integration.⁹ Therefore, the technique was not used for years. It was reintroduced in 1992,¹² substituting the polymer material for titanium. This resulted in an 88% osseointegration rate.¹² Following this, studies demonstrated better success of root-analog implants and described new applications of this technique.^{8,10,11}

¹Assistant Professor, Department of Prosthodontics, Ludwig-Maximilians Universität, Munich, Germany.

²Dentist, Implantat Competence Centrum Munich, Munich, Germany.

³Director and Chair, Department of Prosthodontics, Ludwig-Maximilians Universität, Munich, Germany.

⁴Master Dental Technician, Plattform - Laboratory for Finest Dental Technology, Munich, Germany.

⁵Post Doctoral Researcher, Department of Dentistry, Federal University of Santa Catarina, Florianópolis, Brazil.

⁶Assistant Professor, Department of Prosthodontics, Ludwig-Maximilians Universität, Munich, Germany.

Correspondence to: Dr Anja Liebermann, Goethestrasse 70 – 80336 Munich, Germany. Fax: (+49) 89 4400-59502. Email: Anja.Liebermann@med.uni-muenchen.de

©2017 by Quintessence Publishing Co Inc.



Fig 1 Preoperative full-face and frontal views.

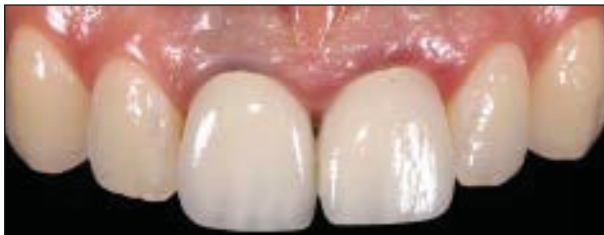
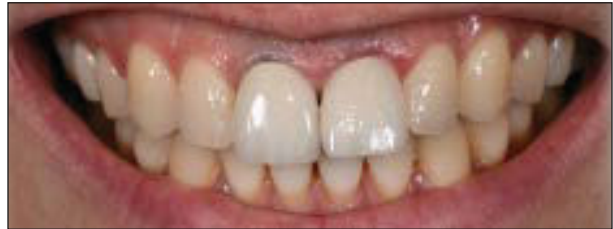
Fig 2 Preoperative intraoral and radiographic views of the dislocated tooth-crown fragment of the maxillary left central incisor.

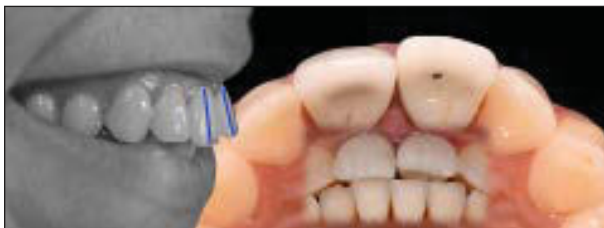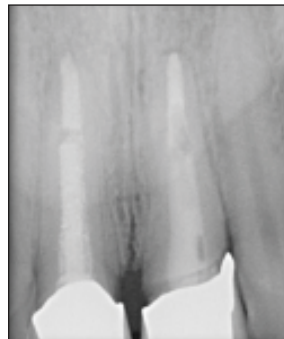


Fig 3 Photographic documentation and analysis for definitive esthetic restorations.

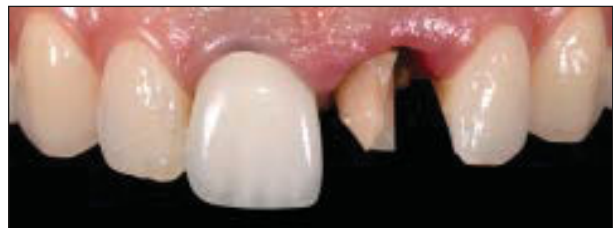

Fig 4 After crown removal, it is possible to observe a deep transverse fracture of the maxillary left central incisor.

The first use of root-analog technique with the goal to include a digital manufacturing process (computer-aided-manufacturing [CAM]) started in 1996 and was constantly improved.¹ One of the main drawbacks was found to be related to the delayed implant insertion many hours after the extraction, caused by the necessary analog impression of the extraction socket, the time-consuming transfer into the computer-aided-design (CAD) process, and finally, the CAM manufacturing process. After the root-analog implant was sterilized, curettage of the blood clot was mandatory to insert the implant many hours after the tooth extraction. Nowadays, the combination of the root-analog technique with digital technology, such as computer-aided-design and computer-aided-manufacturing (CAD/CAM), cone beam computed tomography (CBCT), or digital volume tomography (DVT) offers numerous improvements over the previous techniques. The access to STL and DICOM data

prior to extraction offers numerous improvements by the digital workflow and enables the option to manufacture the root-analog implant prior to the surgical phase. The fully digital replication of the tooth root before extraction enables the placement of the implant with minimal modification of the alveolar socket. This innovative technique is not widely published or used clinically yet.

The goal of this case report is to describe an innovative concept of single-tooth replacement with a root-analog hybrid implant in the esthetic zone. This consists of creating accurate root geometry through CAD/CAM (STL data) and a three-dimensional (3D) visualization (DVT, DICOM data) of the tooth prior to extraction. Besides this tomography, elastomeric or digital impressions are necessary for fabricating the coronal part of the implant. After tooth extraction, the previously fabricated "replicate tooth" can easily be placed. The digital system consists of a customized endosseous titanium root, a zirconia abutment

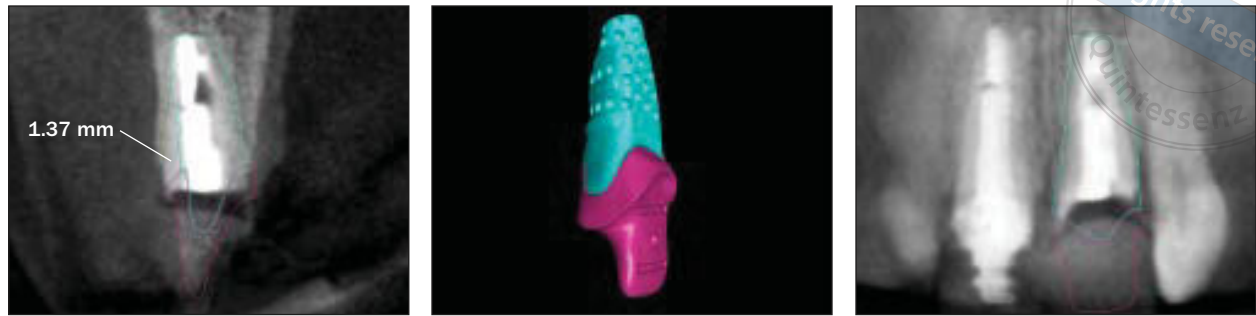

Fig 5 Reduction of 1.37 mm of buccal design, 3D image of the implant, and virtual position of the implant.

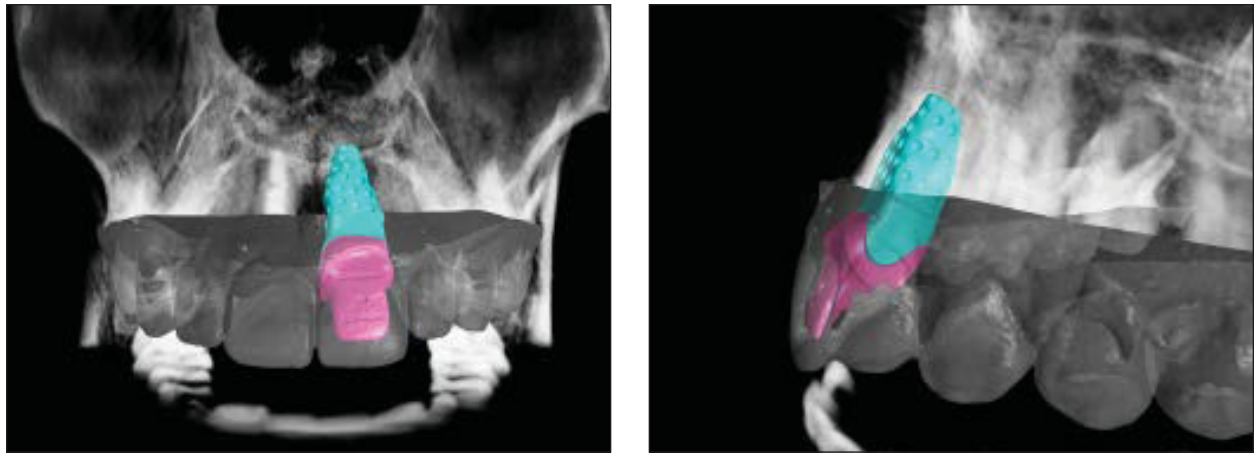


Fig 6 STL data matched with DICOM data.

soldered to the root, and a zirconia provisional protective crown that protects the replicate tooth during the osseointegration process. This technique, previously tested in animal experiments, combines several advantages: minimal bone loss, primary stability through the individual root shape, and immediate implantation through a minimally invasive insertion technique.¹³ Moreover, because the root component of titanium is fused with a glass solder matrix to the zirconia abutment, the undesirable microgap that can result in significant bone loss during the remodeling process can be avoided,¹³ and the gingiva architecture might be maintained.

The detailed steps to use this system, the indications, and the results are described for one clinical case, in which the innovative immediate implant was designed individually for the patient and placed after extraction of the maxillary left central incisor with a very satisfying esthetic and functional result within the esthetic zone.

CASE REPORT

A woman aged 35 years presented to the Department of Prosthodontics of the Ludwig-Maximilians University in Munich with the chief complaint of continuous pain caused by a traumatically fractured maxillary left

central incisor. She was dissatisfied with the esthetic appearance of the maxillary central metal-ceramic restorations. A thorough intraoral examination, a nine-point analysis of the temporomandibular joints (a Krogh-Poulsen test), study casts, a radiographic evaluation, and intraoral and extraoral photographic documentation were performed (Figs 1 to 3).

After the removal of both maxillary central incisor crowns, a deep transverse fracture of the maxillary left central incisor was diagnosed (Fig 4). Consequently, the patient was informed about the necessary single extraction and all treatment possibilities such as fixed dental prostheses (FDPs) or implant rehabilitation. After consideration of all advantages and disadvantages of the different treatment options, the patient decided, together with the dental team, on a single implant. For preservation of soft and hard tissue, an immediate root-analog implant was chosen (the REPLICATE System, Natural Dental Implants). For designing the patient-individual implant, impressions of the maxilla and mandible (Alginate Plus, Orbis Dental) and a DVT were taken. The DVT data with the impression, used to determine the exact dimension of the implant, were sent to Natural Dental Implants (NDI). Utilizing the 3D data derived from the DVT and the digitized casts, NDI designed and fabricated a patient-specific root-analog immediate implant with a predesigned preparation/abutment.

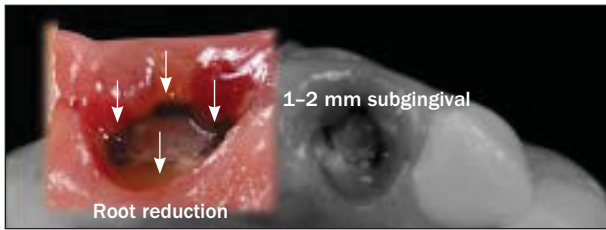


Fig 7 Reduction of the teeth 1–2 mm subgingival to maintain the tissues and allow the placement of provisional restorations.

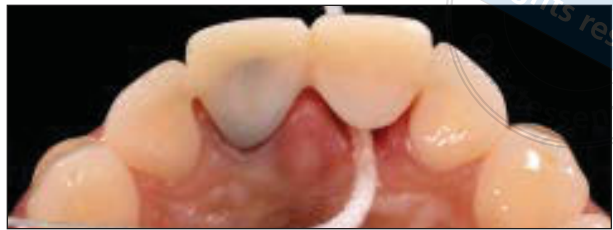

Fig 8 Provisional restorations of the maxillary central incisors for optimal oral hygiene.

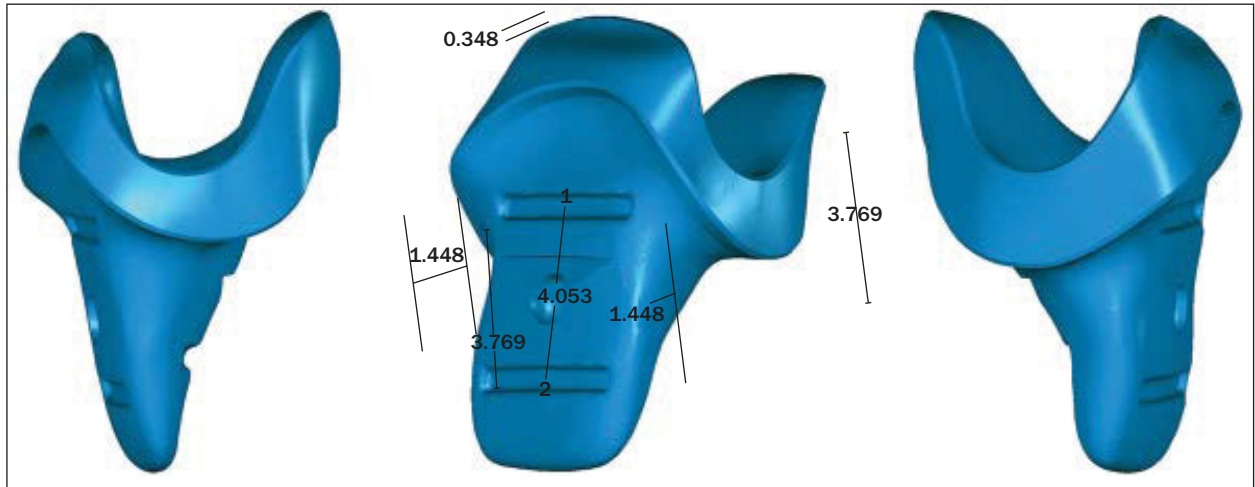


Fig 9 Digitized abutment design.



Fig 10 Patient-individual root-analog hybrid implant.




Fig 11 Platelet-rich plasma is derived from whole blood by sequestering and concentrating the platelets via gradient density centrifugation.

The implant was constructed with a reduced buccal design (approximately 1.4 mm) to accommodate a slight buccal augmentation (Figs 5 and 6), and the zirconia abutment was constructed in a prominent dimension to allow the final preparation according to the undulation of the gingiva after the healing process. Prior to the extraction, the root was reduced approximately 2 mm in the apical direction with a diamond bur to obtain marginal soft tissue (Fig 7). Chairside provisional crowns were fabricated (Luxatemp A2, DMG Chemisch-Pharmazeutische Fabrik), temporarily fixed (Temp Bond, Kerr) on the prepared maxillary right central incisor, and adhesively fixed (Total Etch + Syntac Classic + Tetric Evo Flow of Ivoclar Vivadent)

with wings at the maxillary lateral incisors (Fig 8). The provisional FDP was fabricated with an ovate pontic design for better oral hygiene ability. Figure 9 shows the digitized abutment design.

Implantation

With the root analog implant (RAI) delivered to the dental office prior to the surgical procedure (Fig 10), the maxillary left central incisor was extracted. Before starting the extraction/implantation procedure, a blood sample of whole blood was taken to fabricate platelet-rich plasma (PRP). PRP was mixed with Bio-Oss (Geistlich Biomaterials Vertriebsgesellschaft) for a slight buccal augmentation at a later stage (Fig 11). The remaining

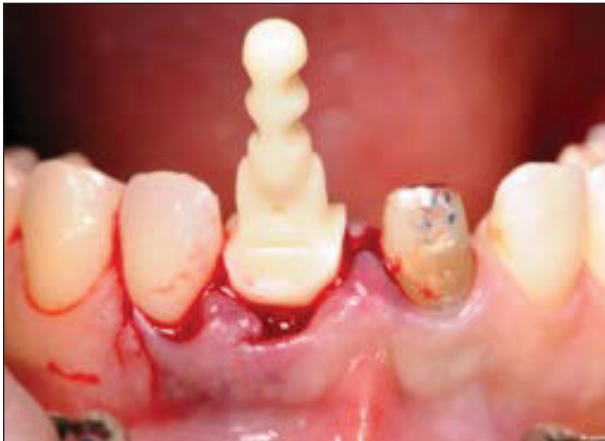

Fig 12 Zirconia try-in analog and the RAI being inserted.

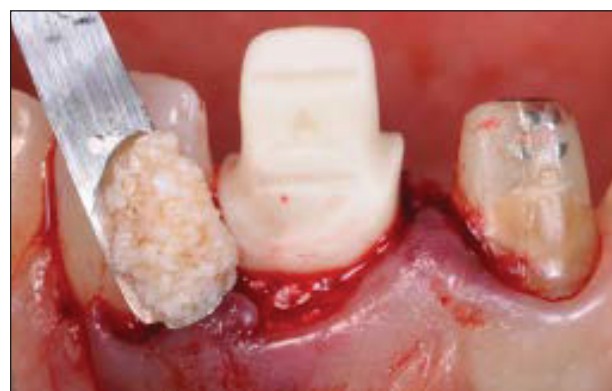
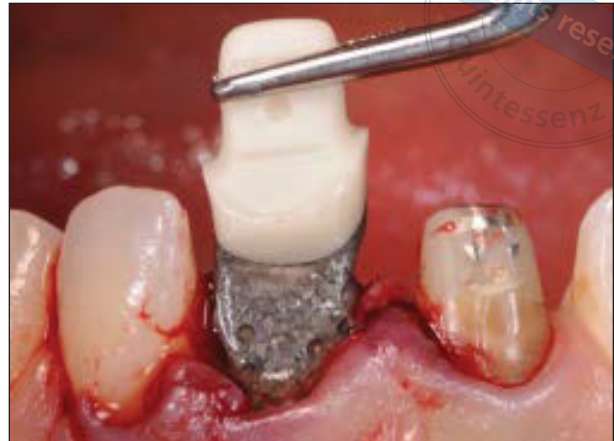
Fig 13 Insertion of Bio-Oss (Geistlich) during RAI insertion.

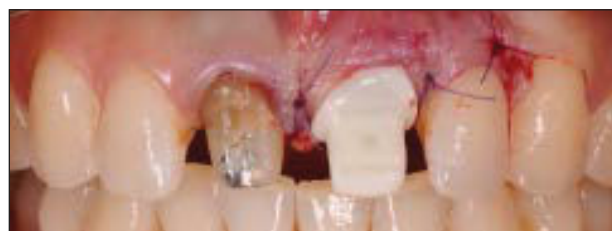
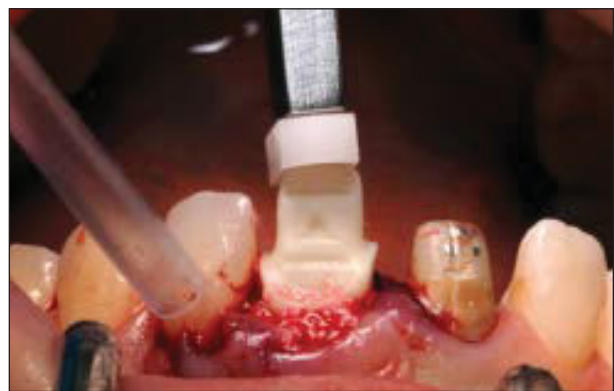
Fig 14 Postimplantation view without restorations.

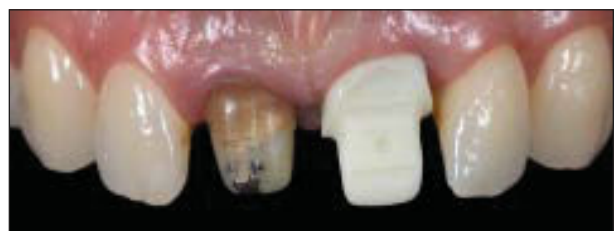

Fig 15 Postimplantation view after 6 months.

tooth root was extracted. This was done with an additional relief cut distal of the maxillary left lateral incisor, necessary because of the prior root fracture. An atraumatic extraction was performed. To avoid injuring or stretching the alveolar socket, no hand lever was used. After thoroughly curetting the socket, the implant position and accuracy of fit were verified with a zirconia try-in analog of the implant provided by NDI as part of the treatment protocol. Small perforations were created in the palatal tissue of the socket to stimulate bleeding. The implant was then inserted and seated with cautious tapping into the socket (Fig 12), and buccal augmentation was achieved with Bio-Oss for stabilizing the tissue architecture (Fig 13).¹³ The relief cut was sewn up with

three single button sutures (Fig 14). The healing of the surrounding tissues is shown after 6 months (Fig 15). After completing the implantation, a baseline radiograph was made. The patient was given instructions about strict oral hygiene and postoperative behavior. Additional antibiotic therapy was not indicated. The 24-hour, 2-week, and 4-week check-ups showed uneventful healing without extra- or intraoral swelling.

Prosthetic Rehabilitation

For the provisional phase, until completed osseointegration at 6 months, the existing connected provisional FDP was ground to be hollow inside the occlusal surface for the left maxillary central incisor. Afterward,

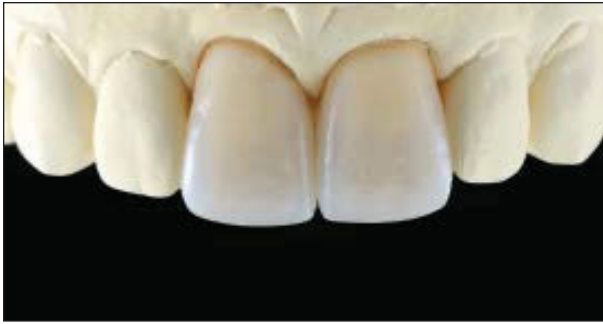

Fig 16 Individually layered zirconia crowns.

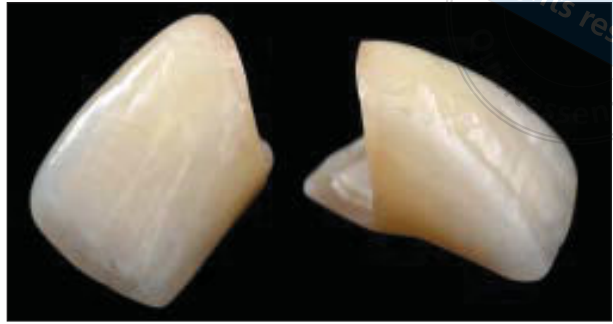

Fig 18 Postoperative maxillary frontal view after 18 months of clinical service.

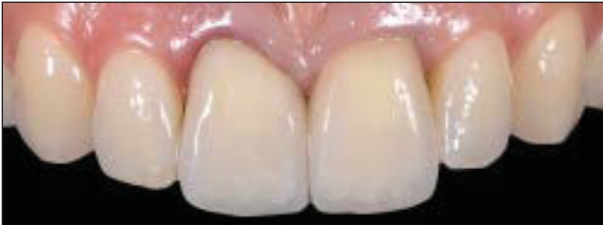

Fig 17 Postoperative maxillary frontal view 2 days after insertion of zirconia restorations.

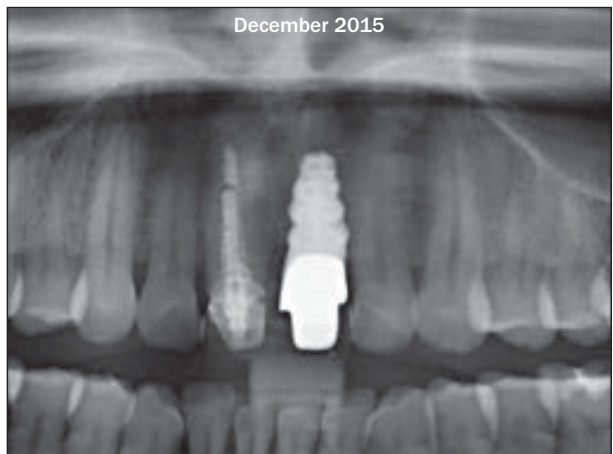
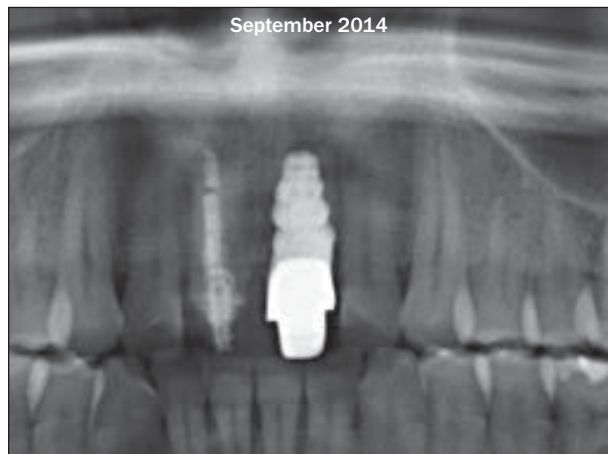
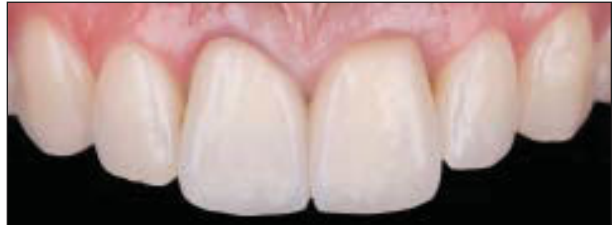

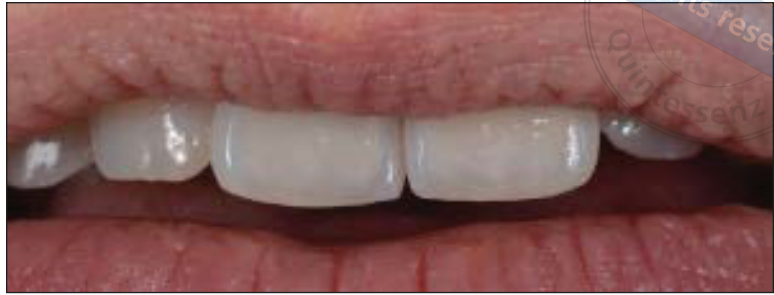Fig 19 Postoperative panoramic radiograph of the maxillary left central incisor in detail after (left) implantation and (right) 15 months of clinical service.

it was relined intraorally with Luxatemp (DMG Chemisch-Pharmazeutische Fabrik) and bonded to the tooth as mentioned earlier. The patient was given instructions to avoid loading the provisional crown during the healing process.

An additional crown lengthening was performed at 6 months post-implant placement on the maxillary right central incisor to gain a better width-to-height ratio of the maxillary front. Newly fabricated provisional crowns, to match the former ones, were placed for an additional 6 months. After this healing period, precise impressions were taken in both arches (Impregum Penta, 3M). For masking the darkened color of the right abutting tooth, a white opaque composite material

was used, and two zirconia ceramic restorations were fabricated (Lava, 3M) (Fig 16).

The definitive restoration was inserted with Multilink Automix (Ivoclar Vivadent) following the manufacturer's instructions (Fig 17). The postoperative intraoral view at 6 months after implant placement and the view at 16 months after implant insertion showed satisfactory esthetics and stability of the surrounding tissues (Fig 18). Comparison of the baseline radiograph taken immediately after implant placement and the radiograph taken 15 months after implant insertion showed stability of the bone (Fig 19). Final profile photos show satisfactory esthetic and functional results (Figs 20 and 21).

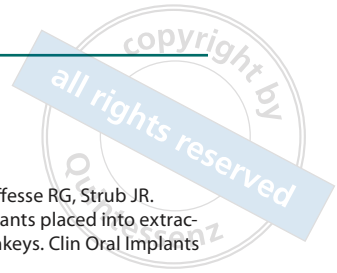
Fig 20 Postoperative lip appearance.**Fig 21** Postoperative photographs of smile appearance.

DISCUSSION

The desire for a minimally invasive treatment and an optimal esthetic outcome represents challenges for the dental team in the replacement of missing teeth, especially in the maxillary front. Significant changes in the dimensions after tooth extraction and their consequences during implant treatment have already been described.^{4,5,11} In addition, the majority of patients have considerable fears of surgical intervention. It makes sense to reduce the number of treatment appointments and surgical procedures to a minimum. This can be achieved today by different methods in the immediate implantation. If expectations are not met satisfactorily, a compromising effect of the implant design and a possible implantation trauma during the osseointegration phase are often referred to. Reducing the number of appointments and surgical interventions is considered as beneficial for reducing patient anxiety. The influence of implant design and trauma during the implantation on final osseointegration is often cited in less-than-satisfactory outcomes. Therefore, a technique that uses a root-analog implant to reproduce the socket dimensions seems to be ideal, allowing the fabrication of a customized implant and reducing the number of surgical interventions.^{3,8,9} The modified technique, proposed in 2009,¹² used a root-analog implant made of titanium that featured macroretentions in the interdental space. The titanium

surface was conditioned by radiation and acid etching to promote the apposition of bone cells and to increase the surface area for bone-to-implant contact (BIC).¹⁴ As a disadvantage, the temporal delay caused by the long preparation and conditioning phase of the root canal is revealed. The titanium surface was prepared by sandblasting to increase bone cell attachment and surface area for BIC.¹² These findings corroborate with the present clinical case.

The CAD/CAM system and DVT technology allow the exact replication of the root geometry of the tooth before extraction and enable the fabrication of patient-individual implants. In this case, these systems were also used to create a hybrid implant that featured a titanium root directly fused with the zirconia abutment. The ability to precisely plan treatment and modify the implant and abutment design to accommodate treatment goals increases the possibility for further beneficial outcomes. Moreover, this innovative concept also uses microretentions on the surface of the implant, corund-blasting, and acid-etching as a surface treatment. Air-abrasion of titanium surfaces increases roughness, surface area, and surface energy; enhances primary stability; and allows a mechanical link to the surrounding tissues, increasing bone formation.^{14,15} Combining the properties of titanium and zirconia enables superior esthetic outcomes. The two materials are fused together into a single piece with a glass solder, sealing the interface between the implant



and abutment. This technique eliminates the common microgap between the implant and abutment, known from conventional implants.¹³

Without the need for resin cement and the absence of an implant-abutment microgap, the risk for bacterial soft tissue inflammation, bone loss, and peri-implantitis might be reduced. Furthermore, no residual monomers can cause tissue or allergic reactions.¹³ This stable connection between the implant and abutment also minimizes the micromovements that are undesirable for bone maintenance. Additionally, the zirconia abutment shows favorable tissue attachment, due to the good biocompatibility and improvement of the quality of surrounding tissue.¹⁶ The one-piece implant avoids the necessity of removing healing caps and abutments, which is unfavorable to the connective tissue attachment and can lead to tissue irritation and alteration on its conformation.¹⁷

High-quality data are important for accurate replication. The dental team should determine the esthetic outcome and precisely plan prior to the placement procedure. It is also important to use the zirconia Try-In analog provided by the manufacturer to check the fit of the implant.

The association of this technology with the root-analog implant technique resulted in a satisfying dental treatment with stable tissues observed at follow-up appointments. This technique offers several advantages including the reduction of appointments, the elimination of excessive heat in the bone socket that occurs when placing screw-type implants, and the ability to plan and achieve esthetic outcomes. The anatomical implant abutment design could improve the hygiene and cleaning potential in the sulcular area for the patient. More studies are necessary in vivo with long-term follow-up.

ACKNOWLEDGMENTS

The authors wish to thank Dr Lynne Opperman for her thorough reading and editing of the manuscript. The authors reported no conflicts of interest related to this study.

REFERENCES

1. Kohal RJ, Hürzeler MB, Mota LF, Klaus G, Caffesse RG, Strub JR. Custom-made root analogue titanium implants placed into extraction sockets. An experimental study in monkeys. *Clin Oral Implants Res* 1997;8:386–392.
2. Busenlechner D, Fürhauser R, Haas R, Watzek G, Mailath G, Pommer B. Long-term implant success at the Academy for Oral Implantology: 8-year follow-up and risk factor analysis. *J Periodontal Implant Sci* 2014;44:102–108.
3. Diz P, Scully C, Sanz M. Dental implants in the medically compromised patient. *J Dent* 2013;41:195–206.
4. Clementini M, Rossetti PH, Penarrocha D, Micarelli C, Bonachela WC, Canullo L. Systemic risk factors for peri-implant bone loss: A systematic review and meta-analysis. *Int J Oral Maxillofac Surg* 2014;43:323–334.
5. Araújo MG, Sukekava F, Wennström JL, Lindhe J. Tissue modeling following implant placement in fresh extraction sockets. *Clin Oral Implants Res* 2006;17:615–624.
6. Passoni BB, Marques de Castro DS, de Araújo MA, de Araújo CD, Piatelli A, Benfatti CA. Influence of immediate/delayed implant placement and implant platform on the peri-implant bone formation. *Clin Oral Implants Res* 2016;27:1376–1383.
7. Brånemark PI, Zarb G, Albrektsson T. *Tissue-Integrated Prostheses: Osseointegration in Clinical Dentistry*. Chicago: Quintessence, 1986.
8. Ghuneim WA. In situ tooth replica custom implant: Rationale, material, and technique. *J Oral Implantol* 2010;36:435–450.
9. Hodosh M, Povar M, Shklar G. The dental polymer implant concept. *J Prosthet Dent* 1969;22:371–380.
10. Pirker W, Kocher A. Immediate, non-submerged, root-analogue zirconia implant in single tooth replacement. *Int J Oral Maxillofac Surg* 2008;37:293–295.
11. Pirker W, Kocher A. Immediate, non-submerged, root-analogue zirconia implants placed into single-rooted extraction sockets: 2-year follow-up of a clinical study. *Int J Oral Maxillofac Surg* 2009;38:1127–1132.
12. Lundgren D, Rylander H, Andersson M, Johansson C, Albrektsson T. Healing-in of root analogue titanium implants placed in extraction sockets. An experimental study in the beagle dog. *Clin Oral Implants Res* 1992;3:136–143.
13. Schwarz F, Alcoforado G, Nelson K, et al. Impact of implant-abutment connection, positioning of the machined collar/microgap, and platform switching on crestal bone level changes. *Camlog Foundation Consensus Report*. *Clin Oral Implants Res* 2014;25:1301–1303.
14. Araújo MG, Linder E, Lindhe J. Bio-Oss collagen in the buccal gap at the immediate implants: A 6-month study in the dog. *Clin Oral Implants Res* 2011;22:1–8.
15. Romanos GE, Toh CG, Siar CH, Swaminathan D. Histologic and histomorphometric evaluation of peri-implant bone subjected to immediate loading: An experimental study with *Macaca fascicularis*. *Int J Oral Maxillofac Implants* 2002;17:44–51.
16. Tetè S, Zizzari VL, Borelli B, et al. Proliferation and adhesion capability of human gingival fibroblasts onto zirconia, lithium disilicate and feldspathic veneering ceramic in vitro. *Dent Mater J* 2014;33:7–15.
17. Degidi M, Nardi D, Piattelli A. One abutment at one time: Non-removal of an immediate abutment and its effect on bone healing around subcrestal tapered implants. *Clin Oral Implants Res* 2011;22:1303–1307.